

Perforator-Pediced Propeller Flaps for Reconstruction of Axillary Defects

WESSAM S. WAHDAN, M.D.; AHMED M. KENAWY, M.D. and AHMED A.E. ALI, M.Sc.

The Department of Plastic Reconstructive Surgery, Faculty of Medicine, Cairo University

ABSTRACT

Perforator flaps represent a recent advance in the reconstructive ladder with reduced donor site morbidity leading to faster recovery and decreased postoperative pain. Perforator flaps combine the reliable blood supply of parent musculocutaneous flaps with reduced donor site morbidity [1]. Perforator flaps have the additional advantages that they can be tailored to accurately reconstruct the defect, including the flap thinning for resurfacing shallow defects, there is freedom of orientation of the pedicle and a longer pedicle is harvested than with the parent musculocutaneous flap [2].

Over the past few years, the use of propeller flaps, which base their blood supply on subcutaneous tissue or isolated perforators, has become increasingly popular [3].

Perforator based propeller flaps that can be used for the coverage of axillary defects include those based on thoracodorsal and circumflex scapular arteries. Fifteen patients with soft tissue defects of the axilla were reconstructed with those perforator flaps in this study and their outcome was evaluated.

Key Words: Axilla – Perforator – Propeller – Flap – Thoracodorsal – Circumflex scapular.

INTRODUCTION

Axillary defects may result from trauma, surgery such as excision of tumors or hidradenitis suppurativa. It may also result after release of post burn axillary contractures. Classifications of post burn axillary contracture were based on either the scar shape or its severity and extension.

Toet and Bosse [4] classified post burn axillary contractures into three types depending on the extent of scarring as follows:

- *Type I:* Both the anterior and the posterior axillary folds are involved, leaving the normal skin in the hair-bearing area. A web is formed during abduction.
- *Type II:* The inner portion of the upper arm and the adjacent trunk and one axillary fold are involved.

- *Type III:* The upper arm and the lateral aspect of the trunk are completely included in one mass of hypertrophic scar tissue.

The perforator propeller flap is a perforator flap, with a skin island made of two paddles, one larger and one smaller, separated by the nourishing perforator that corresponds to the pivot point. The two portions of the skin island can rotate around the pedicle, like the propeller blades around the hub, for as many degrees as the anatomical situation requires (from 90° to 180°). The degree of rotation depends on the relative position of the perforating vessel and the soft tissue defect. A rotation of 180° is possible only if there is available tissue on the other side of the perforator compared with the position of the defect (along the axis connecting the defect and the perforator vessel) [5]. The propeller flap is a useful reconstructive tool that can achieve better cosmetic and functional results. A flap should be called a propeller flap only if it fulfils the definition above. The type of nourishing pedicle, the source vessel and the degree of skin island rotation should be defined for each flap [6].

The aim of this study is to evaluate the versatility of two perforator based propeller flaps that is different in the anatomy of the nourishing vessel and degree of rotation and to evaluate their outcome in the reconstruction of axillary defects.

PATIENTS AND METHODS

The current study included 15 patients with axillary defects resulting from different etiologies; they were eight males and seven female patients of various age groups from 17 to 65 with a mean of 28.5 years. Patients were randomly chosen from those presenting to the Plastic Surgery Department of Kasr El-Aini Hospitals in the period from July 2011 to September 2013. A summary of clinical cases is shown in (Table 1).

Table (1): Clinical characteristics of the patient.

Case number	Age/sex	Etiology of the defect	Defect size/cm	Flap type and size/cm, rotation	Doppler perforator mapping	Donor site closure	Complications
1	28/M	Release of type (II) contracture	20x10cm	Propeller TDAP flap (22x12) cm, 180°	12 and 15cm from axillary crease, 1cm inside anterior border of latissmus dorsi.	1ry closure	Temporary venous congestion
2	33/F	Release of type (III) contracture	20x8cm	Propeller transverse CSAP flap (22x8) cm, 150°	2 and 4cm from triangular space 1cm from lateral border of scapula.	1ry closure +grafting	NO
3	16/F	Release of type (II) contracture	16x8cm	Propeller vertical CSAP flap (18X9) cm, 90°	2cm from triangular space 1cm from lateral border of scapula.	1ry closure	Superficial epidermolysis of the distal tip of the flap.
4	28/M	Release of type (II) contracture	16x8cm	Propeller TDAP (18X9) cm, 90°	12 and 14m from axillary crease, 2cm inside anterior border of latissmus dorsi.	1ry closure	Wound dehiscence (recipient)
5	32/M	Release of type (III) contracture	18x8cm	Propeller transverse CSAP (20x9) cm, 180°	2cm from triangular space 1cm from lateral border of scapula.	1ry closure	Wound dehiscence (donor)
6	26/M	Release of type (II) contracture	20x10cm	Propeller TDAP flap (21x12) cm, 180°	12 and 15cm from axillary crease, 1cm inside anterior border of latissmus dorsi.	1ry closure	Temporary venous congestion
7	31/F	Release of type (III) contracture	20x8cm	Propeller transverse CSAP flap (22x10) cm, 150°	2 and 4cm from triangular space 1cm from lateral border of scapula.	1ry closure +grafting	NO
8	17/F	Release of type (II) contracture	16x8cm	Propeller vertical CSAP flap (18X9) cm, 90°	2cm from triangular space 1cm from lateral border of scapula.	1ry closure	NO
9	28/M	Release of type (II) contracture	16x8cm	Propeller TDAP (18X9) cm, 180°	12 and 14m from axillary crease, 2cm inside anterior border of latissmus dorsi.	1ry closure	NO
10	34/M	Release of type (III) contracture	18x8cm	Propeller transverse CSAP (20x9) cm, 160°	3cm from triangular space 1cm from lateral border of scapula.	1ry closure	Wound dehiscence (donor & recipient)
11	18/F	Hidradenitis suppurative excision	20x8cm	Propeller TDAP (22x10) cm, 150°	14cm from axillary crease 1cm inside anterior border of latissmus dorsi.	1ry closure	NO
12	25/M	Flame burn with raw area of the axilla	20x7cm	Propeller vertical CSAP (21X8) cm, 90°	2cm from triangular space 1cm from lateral border of scapula.	Grafting	Loss of distal 3cm
13	26/M	Flame burn with raw area of the axilla	20x7cm	Propeller vertical CSAP (22X8) cm, 90°	2cm from triangular space 1cm from lateral border of scapula.	1ry closure +grafting	Loss of distal 3cm
14	19/F	Hidradenitis suppurativa excision	20x8cm	Propeller TDAP (22x10) cm, 140°	15cm from axillary crease 1cm inside anterior border of latissmus dorsi.	1ry closure	Wound infection
15	65/F	Release of type (III) contracture, hidden marjoline ulcer	21X7cm	Propeller vertical CSAP (22x8) cm, 90°	2cm from triangular space 1cm from lateral border of scapula.	1ry closure +grafting	NO

Preoperative mapping of perforators:

- Preoperative perforator mapping is performed with handheld Doppler with the patient in the lateral or prone decubitus position to simulate operative positioning.
- Based on previous anatomical studies [7] and [8], the perforators of the thoracodorsal artery are sought out in a region 8cm below the axillary crease (it is an axillary wrinkle which is found at the junction of the upper arm with the shoulder/back region) and within 2cm of the anterior border of the LD muscle. While perforators of the circumflex scapular artery are sought out in a region 2-3cm below the triangular (omotricipital) space and 1cm lateral to lateral border of the scapula [9].
- Six cases were performed as TDAP flap, the remaining nine cases as CSAP flap.
- Operative details.
- General anesthesia was used in all patients.
- Proper positioning of the patient and upper extremity was done either in the lateral decubitus (in cases of TDAP or Vertically-oriented CSAP), prone decubitus (in cases of transversely-oriented CSAP) with the arm abducted 90° (so as to facilitate flap elevation and inseting).
- Dissection is performed under loupe magnification.
- Operative steps.

Propeller thoracodorsal artery perforator flap (TDAP):

- Skin incision along the anteroinferior aspect of the probable skin island in order to detect the thoracodorsal artery and visible septocutaneous perforators.
- Skin incision along the posterior aspect of the probable island. As the dissection was found easier to search for the perforators from mediodorsal to antrolateral aspect of the patient.
- The dissection proceeds in subfascial plane of the latissimus dorsi muscle using blunt ended scissors and bipolar electrocautry.
- Only visible pulsatile perforators are considered suitable and preserved.
- Once a suitable perforator has been identified, the cleavage plane of the latissimus dorsi (LD) muscle in which that perforator resides is devel-

oped where muscle fibers are spread maintaining their longitudinal integrity. The perforator is dissected from the surrounding muscle fibers where they tend to lie in a fibro-fatty layer.

- The main thoracodorsal pedicle is dissected free until the required pedicle length is obtained.

Conversion to muscle-sparing designs:

- When the perforator diameter is less than 0.5mm there is a high risk for perforator avulsion. In this situation a muscle-sparing technique increases safety by preserving a 2-5cm cuff of LD muscle around the perforators.
- Incision of the skin between the pivot point and the recipient site to avoid subcutaneous tunneling of the flap.
- Tension-free flap inset is critical to avoid rupture of the perforator.
- Suction drains are applied both in the recipient and donor sites.
- The donor site is closed primarily.

Circumflex scapular artery perforator flap (CSAP): (Nine cases):

- Design of vertical/transverse skin paddle around the CSA surface marking and perforator Doppler signal around triangular space.
- The flap is then incised along its distal edge, deepening the incision down to the fascia of the back.
- The dissection is followed proximally to the point of origin of the vertical and transverse branches, and the CSA itself (omotricipital space).
- The dissection proceeds until the cutaneous perforator vessel can be clearly identified arising from the superficial aspect of one of these three vessels.
- The flap can then be thinned at the fascial plane separating the deep and superficial adipose layers.
- Tension-free flap inset is critical to avoid avulsion of the perforator.
- Suction drains are applied both in the recipient and donor sites.
- The donor site is closed primarily.

Report of the cases:

Case (7): 31 years old female patient who sustained a flame burn to lt axilla and back 12 year

ago, her burns were allowed to heal spontaneously with resulting type (III) axillary contracture, she was admitted to Plastic Surgery Unit with limited shoulder abduction to only 80° (Fig. 1). Propeller circumflex scapular artery perforator flap measuring 22 x 8cm was designed (Fig. 2). The flap was harvested as described previously by including a cutaneous perforator of the circumflex scapular artery (Fig. 3). The flap then transferred to the defect and sutured in place. The donor site was closed primarily together with grafting due to scarring of the back. The patient was able to abduct her arm to 140° without any difficulty in the post operative period (Fig. 4).

Case (11): 18 years old female patient who presented with lt sided hidradenitis suppurativa of the axilla for 5 years resistant to medical treatment for which she was admitted to Plastic Surgery Unit for excision of this recurrent lesion and reconstruction with propeller TDAP flap 22 x 10cm (Fig. 5)

and (Fig. 6). Together with primary closure of the donor site (Fig. 7). The patient had complete healing of the recipient site without recurrence after regular follow-up.

Case (15): 65 years old female patient with type (III) axillary contracture with severe limitation of shoulder abduction (Fig. 8) resulting from flame burn o the axilla dating 30 years ago with hidden marjoline ulcer discovered accidentally after admission to the plastic surgery unit where she was complaining of bloody foul smelling discharge from the armpit. For which she was investigated with axillary ultrasound and biopsied. The patient was operated for release of the contracture and excision of the tumour with adequate safety margin resulting in exposure of the axillary artery, vein and neural structures. Coverage was done with propeller CSAP flap 20 x 8cm rotated 90° together with 1ry closure and grafting of the donor and recipient sites Figs. (9,10).

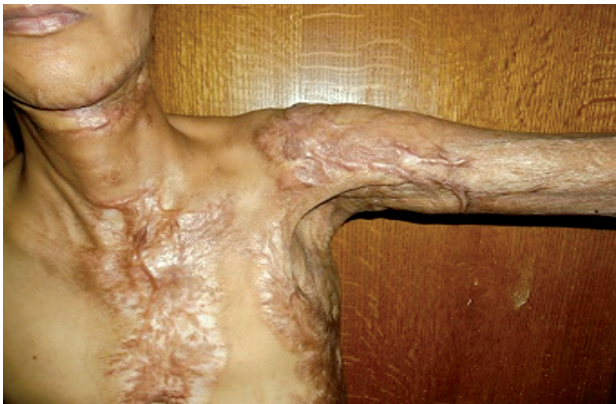

Fig. (1): Female patient with type (III) post. Burn lt sided axillary contracture.

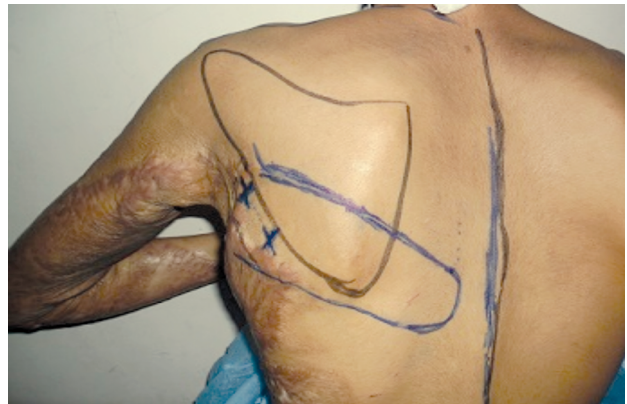

Fig. (2): The same patient; after preoperative marking of the propeller CSAP and the flap with a handheld Doppler.

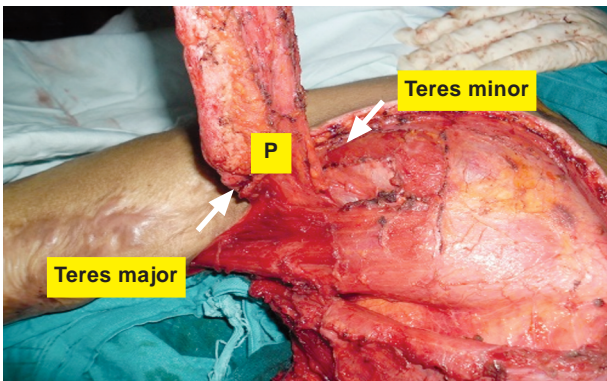


Fig. (3): Circumflex scapular artery in the omotricipital space with perforator seen (P).

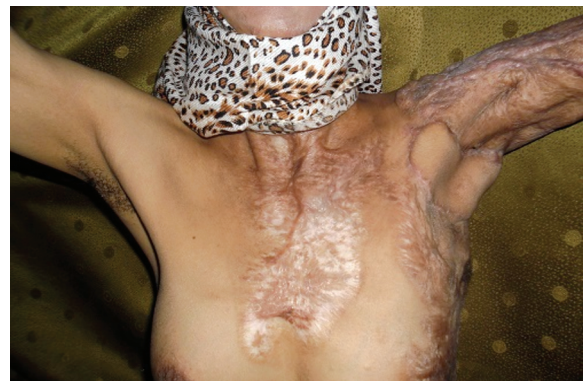

Fig. (4): The same patient four months after discharge with complete healing of the flap and improved degree of shoulder abduction.

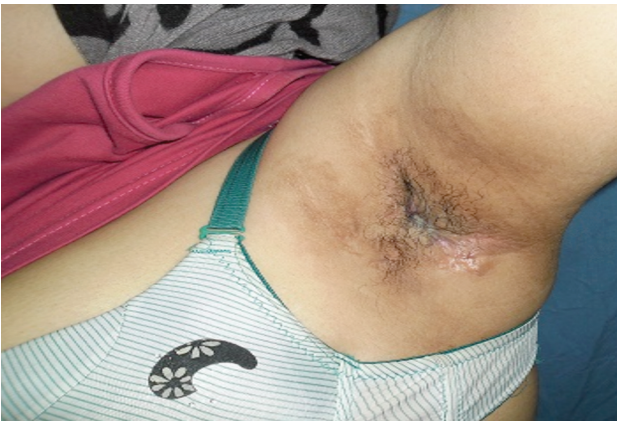

Fig. (5): Female patient with Lt sided axillary hidradenitis suppurativa together with design of propellar TDAP flap.

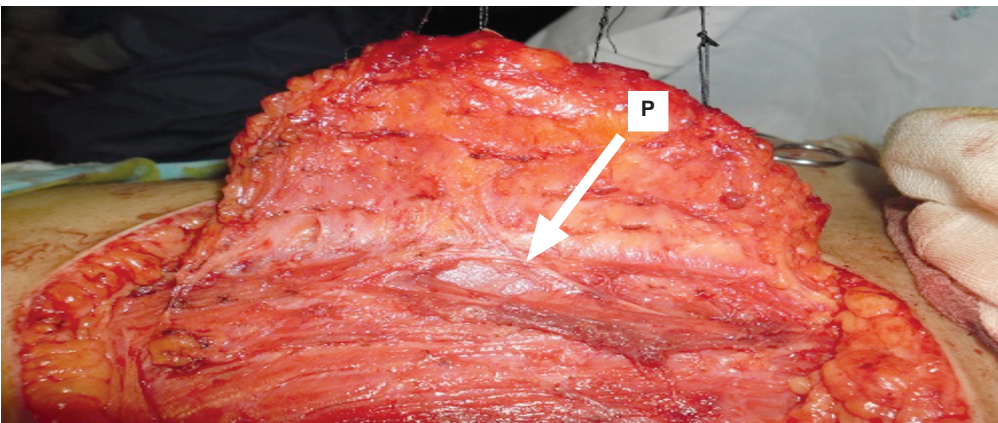


Fig. (6): The same patient; intraoperative view showing reliable musculocutaneous perforator (P).

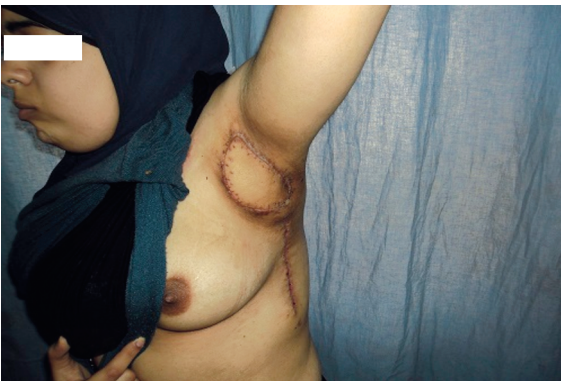

Fig. (7): The same patient after excision of the lesion together with reconstruction using propellar TDAP flap with 1ry closure of the donor site.

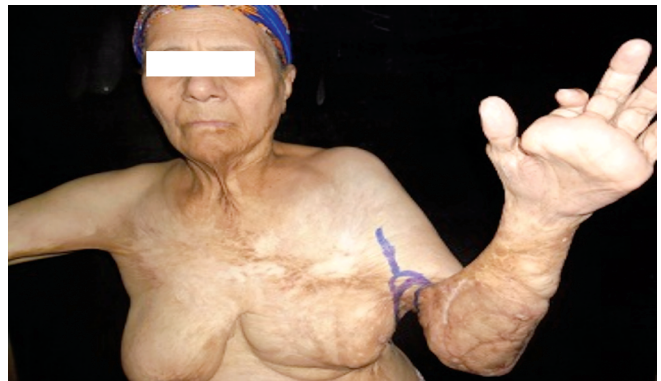

Fig. (8): 65ys old female patient with type (III) axillary contracture with hidden squamous cell carcinoma inside the contracture.

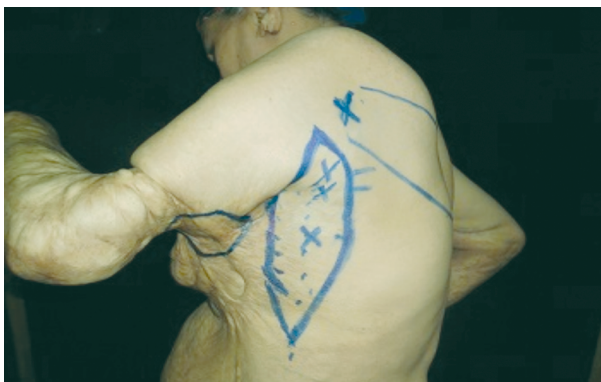

Fig. (9): The same patient with preoperative marking of the perforators of the thoracodorsal and circumflex scapular arteries.

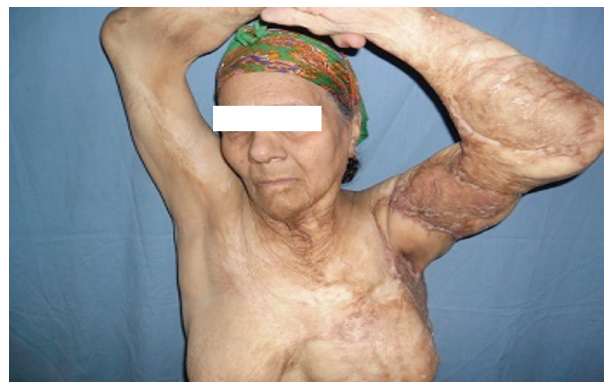

Fig. (10): The same patient; five months postoperative with complete healing of the wound. With improvement in the degree of shoulder abduction.

RESULTS

40% of the axillary defects were reconstructed using Propeller TDAP flap while the remaining 60% were reconstructed using propeller CSAP flap. Twelve flaps survived completely without even marginal necrosis of which six flaps were done as TDAP and the remaining six cases as CSAP, three CSAP flaps developed distal congestion and necrosis of the most distal part. Donor sites were closed completely primarily in ten cases, while grafting was done in addition to partial donor site lry closure in four cases and grafting only was done in one case due to partial affection of the donor site with full thickness burn. The results and clinical characteristics of the patients are given in (Table 1).

DISCUSSION

The perforator propeller flap is comparable to a local flap in terms of amount and firmness of subcutaneous tissue, skin texture, and the possibility of replacing “like with like”. Similar to a local perforator flap, it is characterized by freedom of choice of skin island shape and dimension and safety of perfusion. Compared with a free flap, it requires a simpler operation and shorter operating times and without the staff expertise and complex logistical setup [10].

Propeller flaps can have the same complications as any other flap, particularly perforator flaps. Venous congestion, either at the tip of the flap that had been documented in three cases of this study or, more rarely, along its entire length, is the most frequent complication.

It can be caused by an insufficient flow in the perforating vessel (whether because of intrinsic vessel characteristics or because of external damage) or by inadequate release of the fascial adhesions around the vascular pedicle and especially around the vein [11].

Accurate dissection of the perforator for a distance as long as possible toward the source vessel, are of paramount importance to reduce the risk of vascular complications [12]. It has been demonstrated that the risk of vessel buckling is decreased when, the perforator is of 1mm diameter, and the vessel length is more than 3cm [11].

In the previous description by Kim et al., 2001 [13]. Harvesting TDAP flap was started with an incision at the anteroinferior aspect of the flap and then to proceed for dissection of the musculocuta-

neous or septocutaneous perforators after identification of the anterior border of the latissimus dorsi muscle.

In the current study as regard TDAP flap harvesting, the operative procedure is started by incising the anteroinferior aspect of the planned flap in order to identify the anterior border of the latissimus dorsi muscle, to expose the main thoracodorsal bundle and any visible sizable septocutaneous perforators then we incise the posteriomedial aspect of the planned flap to search for the perforators whose sites were marked preoperatively with the handheld Doppler; as the dissection was found easier to survey from mediadorsal to antrolateral aspect of the patient. The dissection proceeds in subfascial plane of the latissimus dorsi muscle using blunt-ended scissor and bipolar electrocautry till we find a reliable pulsatile perforator, once identified we continue intramuscular dissection till the main thoracodorsal pedicle. We have dissected the lateral branch of thoracodorsal artery proximally until its junction with the main trunk. Usually the horizontal branch is divided to obtain enough pedicle length. Thoracodorsal nerve wasn't divided to protect the muscle from denervation atrophy.

In several cases the dominant dissectible perforator was situated in a location more caudal to the axillary fold (12-14cm caudal to the posterior axillary fold), the perforators do not emerge in aline along the muscle fibers which means that the number of the available perforators is restricted if partial muscle destruction is to be avoided.

In the current study also nine CSAP flaps had been performed either in the form of vertical or transverse propeller island designs, it had been agreed with Dabernig et al., 2007 [9]. In that CSAP flap involves no intramuscular dissection, has a very well localized main pedicle and the character of skin raised can be varied by adjusting the orientation of the flap. The flap had been elevated from distal to proximal starting at the distal edge of the flap with incision deepened to the fascia then the dissection is followed proximally to the point of origin of the vertical and transverse branches and The CSA itself (omotricipital space), the dissection proceeds until the cutaneous perforator vessel can be clearly identified arising from the superficial aspect of one of these three vessels. And then the flap can be thinned at the fascial plane separating the deep and superficial adipose layers. It was found a more easy and safe procedure.

Conclusion:

The perforator propeller TDAP and CSAP flaps are versatile options for reconstruction of axillary defects it can be elevated safely to meet the size required even in the largest defects. The donor site scar may be considered as acceptable considering the functional gains.

REFERENCES

- 1- Kroll S.S. and Rosenfield L.: Perforator-based flaps for low posterior midline defects. *Plast. Reconstr. Surg.*, 81: 561-566, 1988.
- 2- Koshima I. and Soeda S.: Inferior epigastric artery skin flap without rectus abdominis muscle. *Br. J. Plast. Surg.*, 42: 645-648, 1989.
- 3- Moscatiello F., Masia` J., Carrera A., Clavero J.A., Larran`aga J.R. and Pons G.: The "propeller" distal anteromedial thigh perforator flap: Anatomic study and clinical applications. *J. Plast. Reconstr. Aesthet. Surg.*, 60: 1323-1330, 2007.
- 4- Toet L. and Bosse J.P.: The use of scapular skin island flaps in the treatment of axillary post burn scar contractures. *Br. J. Plast. Surg.*, 47: 108, 1994.
- 5- Teo T.C.: Perforator local flaps in lower limb reconstruction. *Cir. Plast. Ibero-Latinoam*, 32: 15-16, 2006.
- 6- Hyakusoku H., Yamamoto T. and Fumiiri M.: The propeller flap *Br. J. Plast. Surg.*, 44: 53-54, 1991.
- 7- Angrigiani C., Grilli D. and Siebert J.: Latissimus dorsi musculocutaneous flap without muscle. *Plast. Reconstr. Surg.*, 96: 1608-1614, 1995.
- 8- Spinelli H.M., Fink J.A. and Muzaffar A.R.: The latissimus dorsi perforator-based fasciocutaneous flap. *Ann. Plast. Surg.*, 37: 500e6, 1996.
- 9- Dabernig J., Sorensen K., Shawdunn J. and Hart A.M.: The thin Circumflex scapular artery perforator flap. *J. Plast. Reconstr. Aesthet. Surg.*, 60: 1082-1096, 2007.
- 10- Pignatti M., Pasqualini M., Governa M., Bruti M. and Rigotta G.: Propeller flaps for leg reconstruction. *J. Plast. Reconstr. Aesthet. Surg.*, 61: 777-783, 2008.
- 11- Wong C.H., Cui F., Tan B.K., et al.: Nonlinear finite element simulations to elucidate the determinants of perforator patency in propeller flaps. *Ann. Plast. Surg.*, 59: 672-678, 2007.
- 12- Selvaggi G., Anicic S. and Formaggia L.: Mathematical explanation of the buckling of the vessels after twisting of the anastomosis. *Microsurgery*, 26: 524-528, 2006.
- 13- Kim J.T., Koo B.S. and Kim S.K.: The thin latissimus dorsi perforator based free flap for resurfacing. *Plast. Reconstr. Surg.*, 107: 374-382, 2001.